

Walking Forward

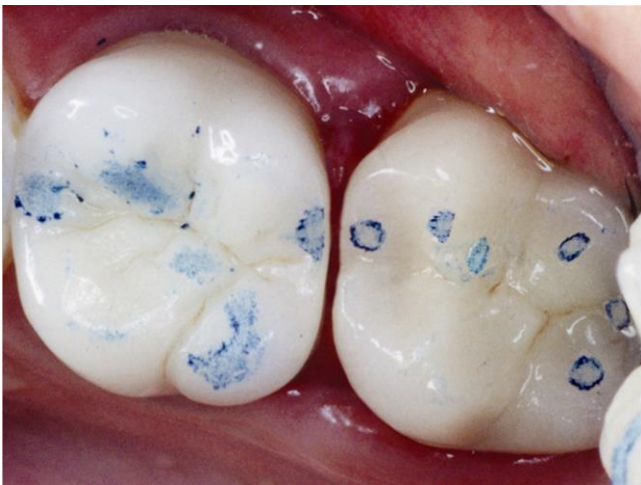by Rod Kurthy, DMD

updated 1/2019

Dealing with unwanted posterior open interproximal contacts

An occlusal adjustment technique that may save your...sanity

You insert a crown. Nice, tight contact. Good occlusion. You see the patient 6-12 months later, only to find a space between that crown and the adjacent tooth that you could drive a truck through!



The patient complains of constantly getting food trapped in the space, and when you look, you see the interproximal gingival tissue looks like raw hamburger.

What the heck went wrong?! Obviously, this is an occlusal problem.

Does this only happen with new crowns? No. You may see this happen after virtually any type of new restoration. And of course, you have new patients presenting with open posterior contacts that trap food and drive the patients nuts. And sometimes those new patients are downright angry with their previous dentist because of the open contacts!

And if you've been practicing for at least a few years in the same location, you've seen patients with virgin teeth that even develop these open contacts with food traps. Just the slow, constant occlusal wear over time changes the occlusion, sometimes resulting in these spaces opening up.

So you replace the new crown that drifted distally. You make absolutely certain the interproximal contact is tight and the occlusion is good. And 6 months later...SAME THING happens! And by this time, your patient pretty much thinks you're a quack. No, you're not alone. I hear this all the time.

When you check the occlusion of the distalized molar, as you see in the photo above, the occlusion is stable. So that space is not going to close on its own.

What Do You Do Now?

How do you address the open contact?

- Place a class 2 filling on the adjacent tooth? That's what I was taught decades ago in dental school.
- Replace the crown? And if you do replace the crown, do you charge the patient? Charge a lab fee? No charge at all?
- Tell the patient to just carry some dental floss with them? – don't laugh – I've actually heard dentists say this is what they do.
- And if you replace the crown, and the same thing happens again...what then? You talk about embarrassing!

The Concept

It's all about force vectors. We're not just talking about "the bite" in centric occlusion. We're dealing with all the excursions the patient makes consciously, subconsciously, asleep and awake. If you're able to get your patient to go through all possible excursions with articulating paper, you're a much better dentist than I am.

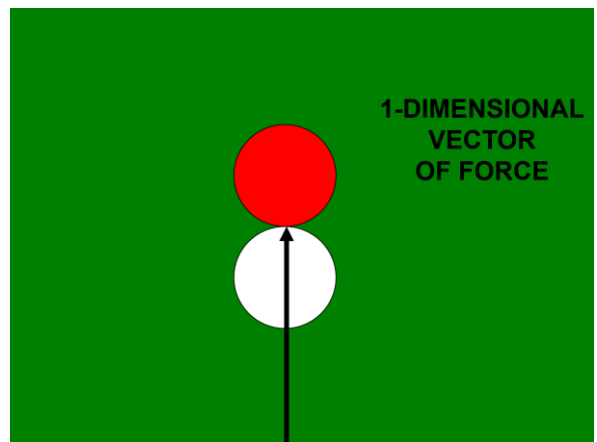
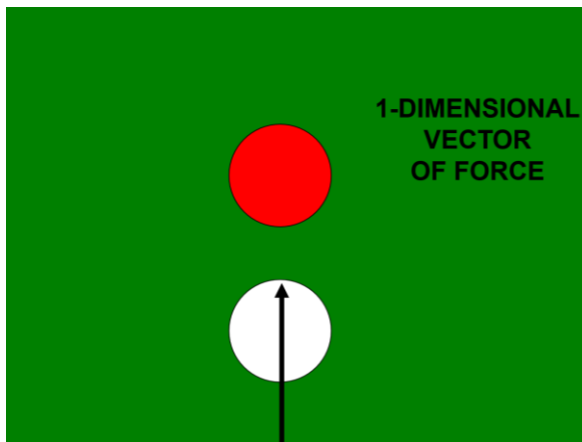
Even if the centric occlusion is dead-on, all it takes is for the patient, while eating, while sleeping or any other time, to prematurely hit some incline repeatedly just enough to cause the tooth to move a tiny bit. As it moves, more incline planes come into contact, resulting in different vectors of force, moving the tooth more. It's your classic "dominion effect".

Force Vectors

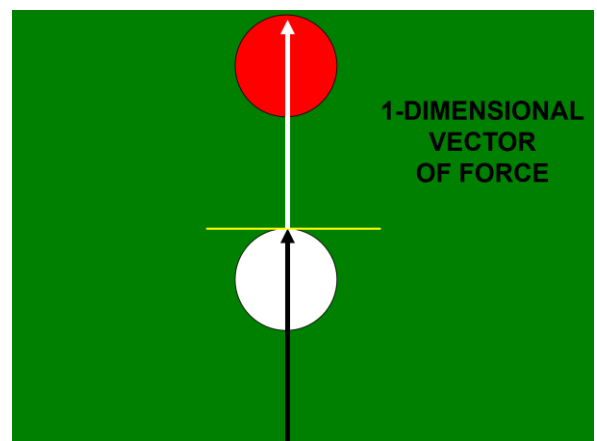
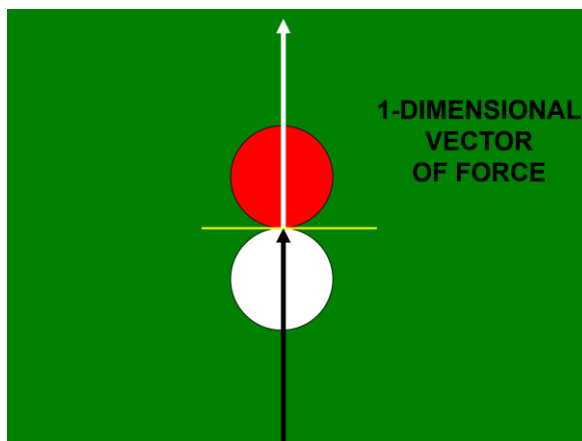
Using the analogy of a pool table and pool balls, you'll be able to better understand force vectors:

1-Dimensional Vectors of Force

Let's first talk about 1-dimensional vectors of force. If you want the red pool ball to move straight forward, you try to hit the red ball dead-center with the cue ball.



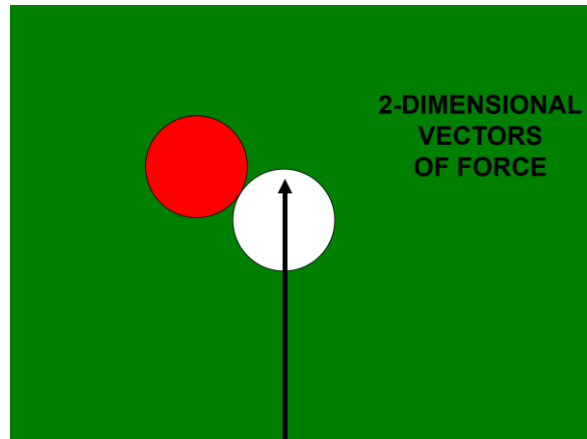
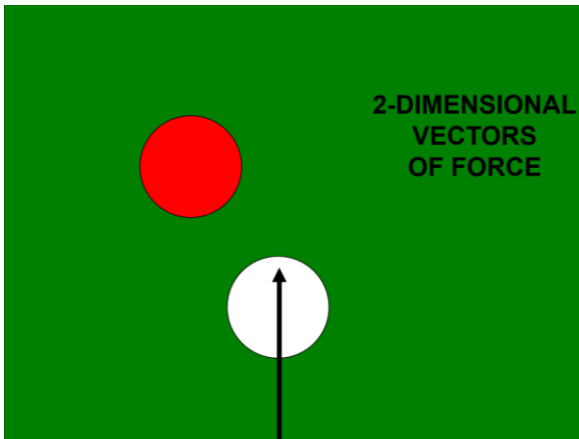
Where the two balls first touch, draw a line (yellow line below) parallel to the point of contact of the cue ball and the red ball. The vector (direction) of force (white arrow) will ONLY be perpendicular to the yellow line. This SINGLE vector of force will push the red ball forward (white arrow), perpendicular to the yellow line.



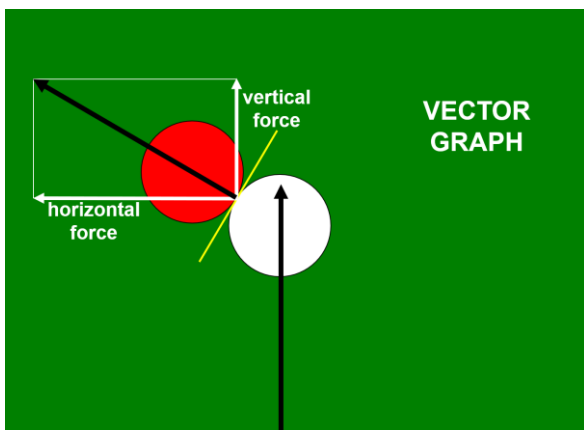
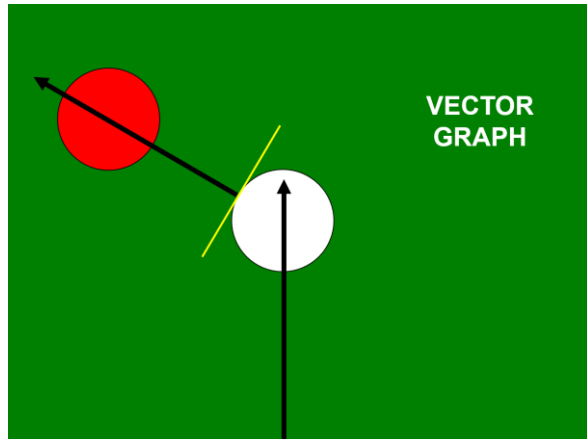
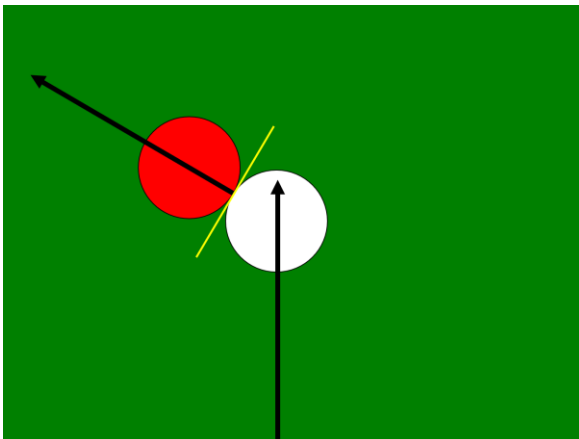
But of course, with occlusion, we're dealing with 3-dimensional vectors of force. I haven't figured out how to diagrammatically show you 3D vectors, but showing 2-dimensional vectors of force will give you a good understanding of what is happening.

2-Dimensional Vectors of Force

Let's say we want to hit the red pool ball with the white cue ball, and make the red ball go at an angle (instead of straight forward)



Again, where the two balls first touch, draw a line (yellow line below) parallel to the point of contact of the cue ball and the red ball. The red ball will then be pushed somewhat sideways and forward in a direction perpendicular to the yellow line.



So, why will the red ball be pushed in the exact direction shown, and why does this represent 2-dimensional vectors of force? To answer this, we need a Vector Graph. When the white cue ball hits the red pool ball, it generates a force moving straight forward (vertical force), and a force directly to the left (horizontal force). Depending on exactly where on the red ball the white ball hit, there will be a certain amount of force in both directions. On the left you see the horizontal force is about twice the vertical force. When you plot these amounts of force on the graph, you can draw a line from where the white and red balls hit, to that point on the

graph, and this shows the direction of movement of the red ball (which always is perpendicular to the yellow line).

But teeth (having 3-dimensional vectors of occlusal force) are far more involved, because we're dealing with forces in all three dimensions. And teeth have numerous cuspal inclines that, when occluding, hit each other in different places, at different angles, resulting in many vectors of force on the teeth. And of course, just like with orthodontic treatment, we know that force causes teeth to move.

THE 2 CAUSES OF DISTALIZED MOLARS:

1) Cuspal Incline Planes Cause Force Vectors (moves the crown of the tooth horizontally)

In the remaining portion of this paper, I show the offending distalized tooth as being a lower 2nd molar. However, realize that problems and solutions I discuss below also apply to distalized upper molars.

In the illustration to the left, the blue tooth represents the new crown you have just placed. Notice that the interproximal contact is fully closed and tight.

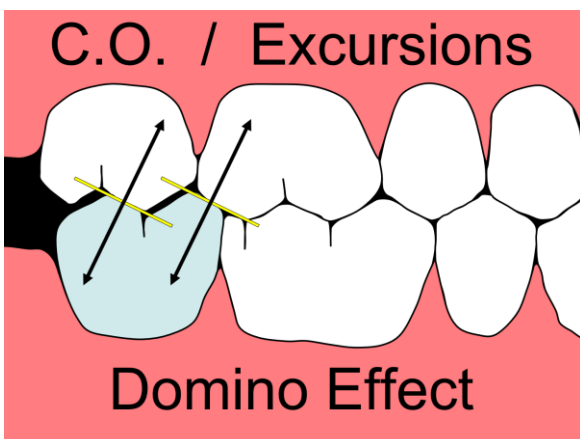
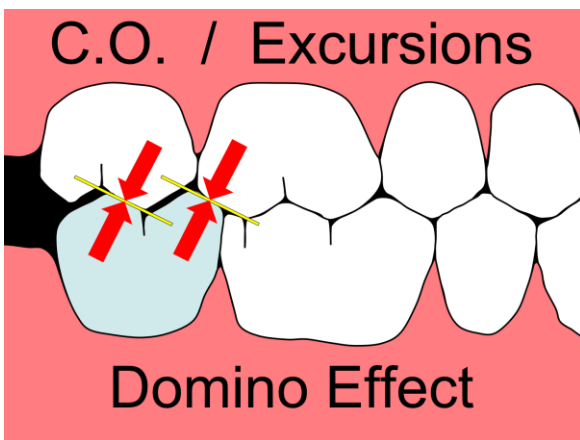
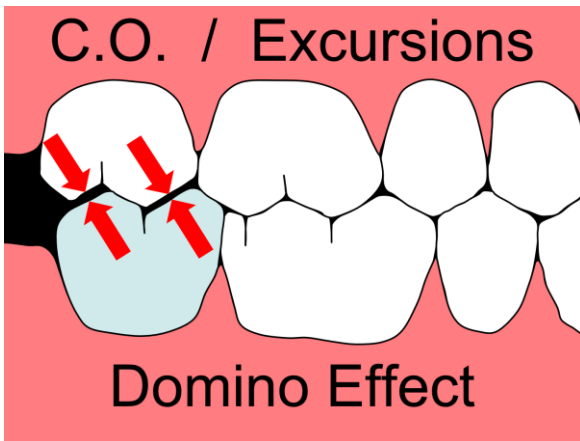
Notice (between the red arrows) the portions of the teeth that are not in occlusion. I have shown these as being "far out of occlusion" only so you can easily see them. In reality, the "open occlusion" in these areas may typically measure only a few microns.

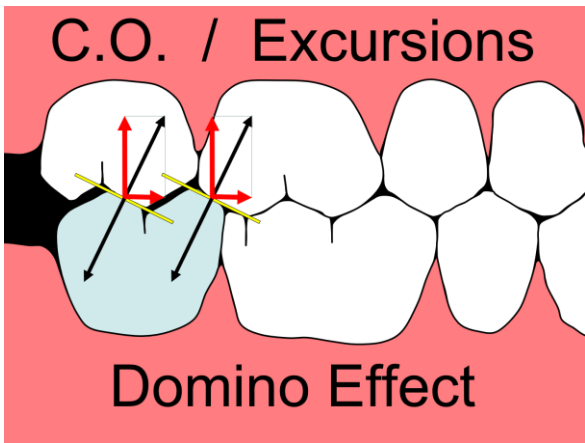
It is important to understand that everything I show below regarding opposing teeth hitting may occur in centric occlusion or in any excursions.

To the left you see the same diagram as above, except here the red arrows now point to where opposing teeth do firmly contact each other.

And again, we have drawn yellow lines parallel to the contact points where upper and lower tooth structure hits.

Now we can draw our force vectors and the direction of those forces on both upper and lower teeth. When the upper and lower teeth hit, force is applied to both upper and lower teeth equally.



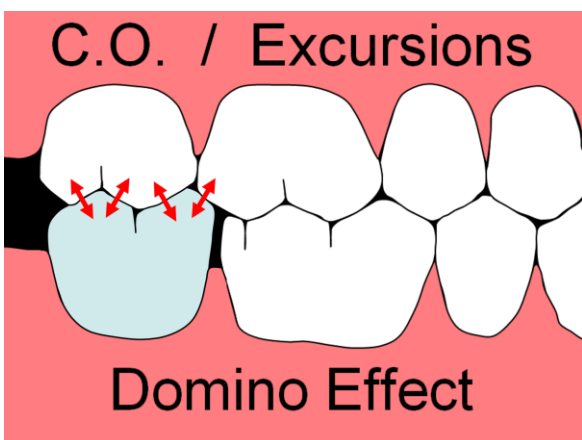
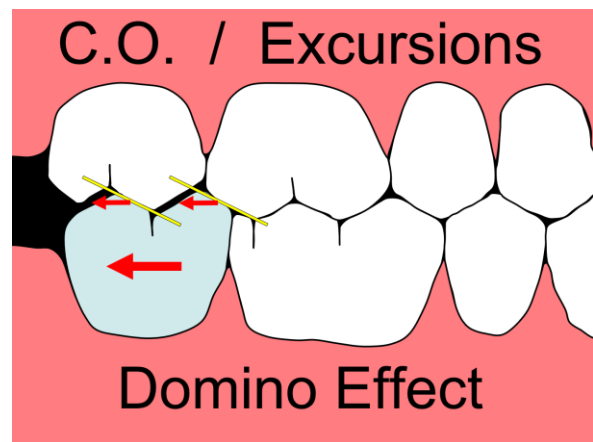
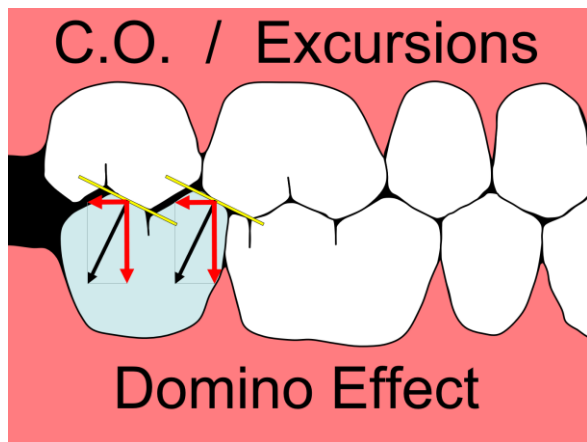


Next we draw our vector graphs for the upper teeth, showing the vertical and horizontal forces on the upper teeth as red arrows. First look at the vertical red arrow forces, which want to intrude both upper molars. But given that the occlusal force is not constant (because the teeth are not always in forceful occlusion), the periodontal ligament (PDL), acting as a sling, will not allow the teeth to migrate apically (intrude).

Now look at the red arrows representing the horizontal vectors of force. These forces want to move those molars "forward" (mesially). But again, the occlusal force is not constant, and all of the contacts between the bicuspids

and anterior teeth resist any mesial migration of those upper molars. So, in a practical sense, the forces on the upper teeth are neutralized, and no unwanted tooth movement occurs.

Below on the left, look at the vectors of force (red arrows) on the lower new crown. You have a vertical force wanting to intrude the crown. But again, the PDL and lack of constant occlusal force neutralizes this force. So, below on the right you see that all you're left with is the horizontal vectors of force in the distal direction. Given that there is nothing to prevent easy distal migration, even intermittent forces will move the tooth distally.

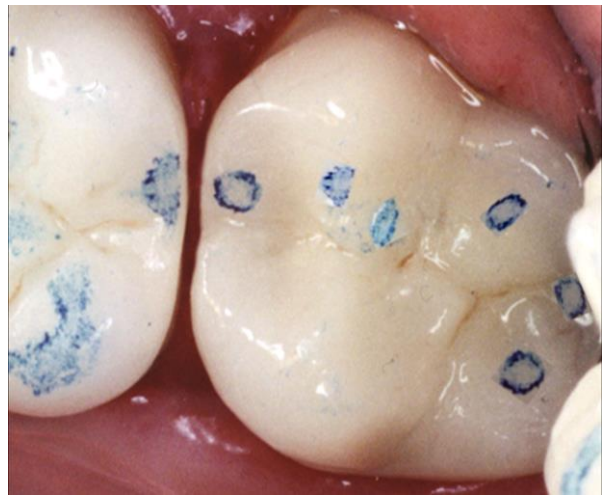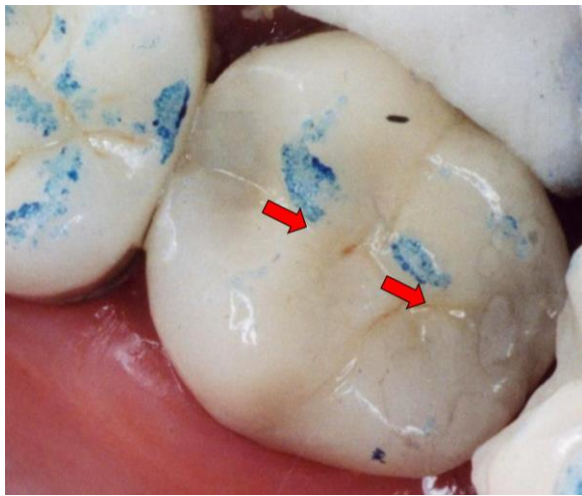


On the left you now see the distalized crown. Also see that now the tooth has come into a stable occlusion, with distal forces counteracted by mesial forces. But of course, we are left with the problem of the wide-open interproximal contact and food trap between the lower first and second molars.

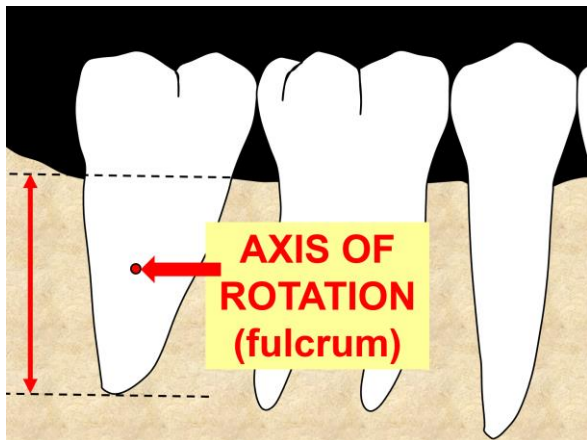
Pretend you just inserted the second molar crown you see below on the left. Notice where the occlusal markings are. Remember, this could be in centric occlusion or any excursion. These marks are on the

mesial inclines of cusps, generating vectors of force (red arrows) distally. This crown is destined to migrate distally.

Below on the right, you see the tooth after it has migrated distally and come into a stable occlusion, where the mesializing forces equal the distalizing forces.



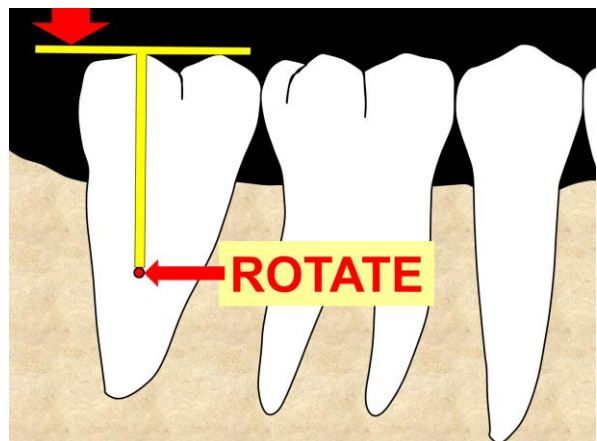
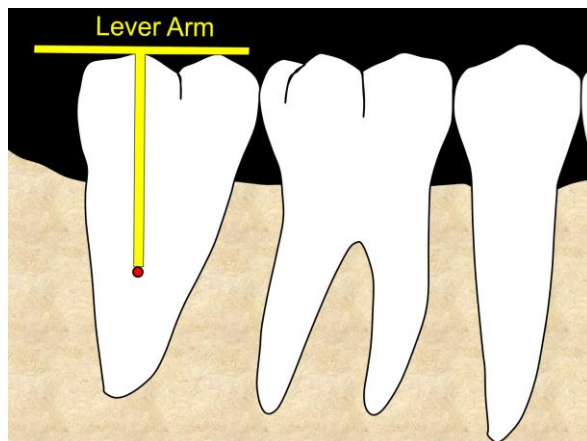
2) Marginal Ridges Cause Vertical Forces (tilts the tooth mesially or distally)

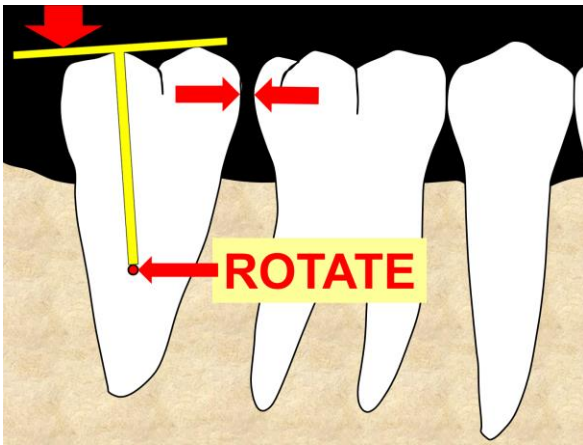


Remember that teeth do not naturally move “bodily” through bone. Instead, they “tilt” in the bone. If you want to move a tooth through bone without having it tilt, the tooth must be bracketed and moved orthodontically through the bone.

On the left, the 2nd molar represents the tooth that may migrate distally. The dashed black horizontal lines show the “anchorage” of the molar root in the bone. The red dot in the middle of the root indicates the axis of rotation the tooth will rotate around as it tilts mesially or distally.

Below on the left I have diagrammatically placed a yellow lever arm over the molar. Then below on the right I’ve placed vertical force (large red arrow) downward onto the distal end of that lever arm, representing vertical force on the distal marginal ridge. This causes a vertical apical force wanting to rotate the tooth distally.

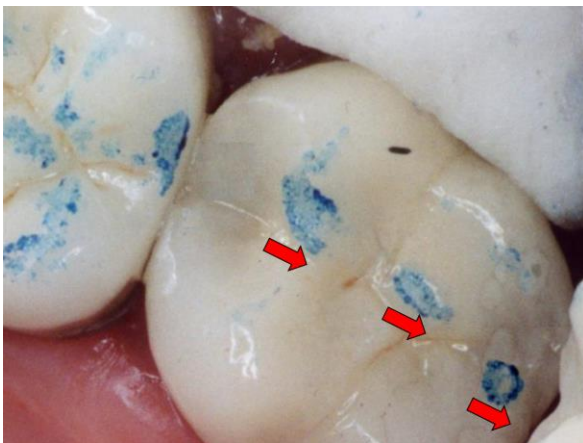




This force on the distal marginal ridge does cause the tooth to rotate (tilt) distally, opening up the interproximal contact.

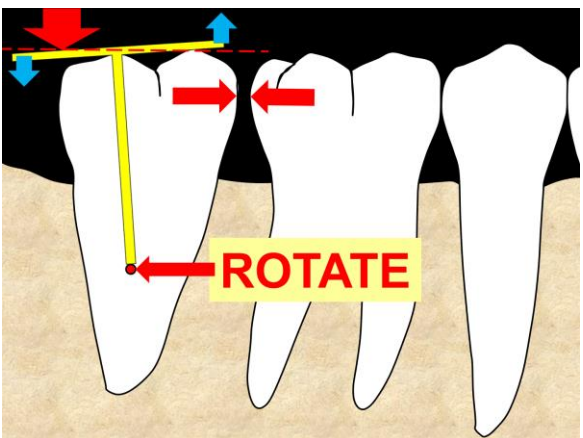
Both Causes of Distalization Combine to Move the 2nd Molar Distally

- 1) Cuspal Incline Planes Cause Horizontal Force Vectors
- 2) Marginal Ridges Cause Vertical Forces Resulting in Tilting of the Molar



Let's combine both "causes" and see what happens. Again, you've just inserted the new crown. And like the photo I showed you above, you have the marks on the mesial inclines of cusps, causing distalizing vectors of force wanting to push (rotate) the tooth (horizontally) distally. But now, in the photo to the left, you ALSO have a mark on the distal marginal ridge, causing vertical apical force, resulting in rotating the tooth distally. Both potential causes now combine to move the 2nd molar distally even faster.

But rotation is more complicated – there is another very important consideration. Again...this is important, so make sure you understand the following concept:



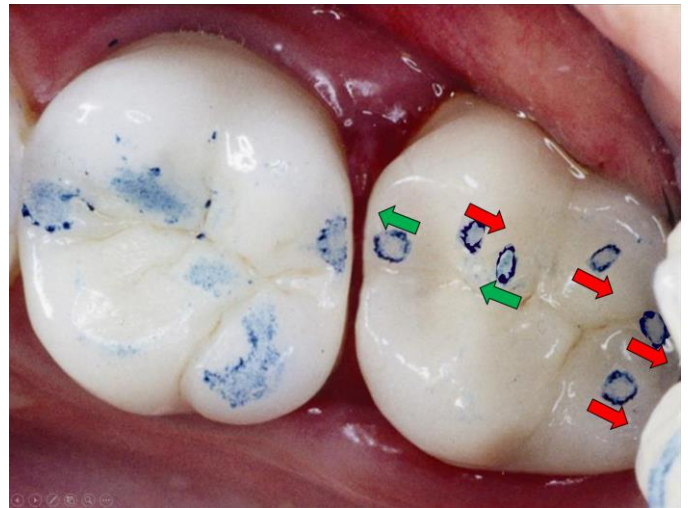
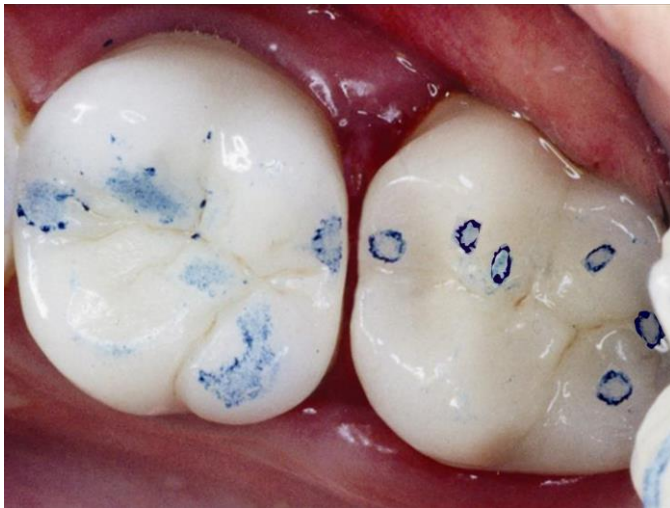As the tooth rotates distally around the axis of rotation, the distal marginal ridge becomes lower (it sort of "intrudes"), and the mesial marginal ridge raises up (it sort of "erupts"). This is shown on the left with the blue arrows.

The horizontal red dashed line represents where the top of the yellow lever arm was prior to the tooth rotating distally. Notice how the distal of the yellow lever arm (distal marginal ridge) has intruded below the red dashed line. And how the mesial of the of the yellow lever arm has erupted above the dashed line. Remember this – I'll come back to it later.

In the photos below you see the tooth has distalized and come into a stable occlusion. You have:

- Mesializing and distalizing vectors of force from cuspal inclines cancelling each other out.
- Vertical forces on both mesial and distal marginal ridges cancelling each other out. Prior to the distalizing of the molar, the mesial marginal ridge was not in occlusion. As the tooth rotated distally, the mesial marginal ridge “erupted” and came into occlusion. As soon as the mesial marginal ridge came into occlusion, the distalizing movement ceased.

It is important understand that when the tooth rotated distally, resulting in the coronal movement (eruption) of the mesial marginal ridge, the mesial marginal ridge finally came into occlusal contact. Once the mesial marginal ridge came into occlusal contact, the mesial could not “erupt” anymore – therefore the tooth could not rotate distally anymore – and therefore the distalization movement of the tooth stopped.



AN IMPORTANT CONCLUSION: When rotating distally, the entire mesial half of the tooth will raise up (erupt), and the entire distal half of the tooth will sink down (intrude).

LET'S FIX IT! LET'S WALK THE TOOTH FORWARD (MESIALLY)

In the photo above on the right, all of the red and green arrows I've shown you next to articulating paper marks on the occlusal of the crown can be thought of as “friends” (green arrows) and “enemies” (red arrows).

How do we fix the problem and **Walk the Tooth Forward** to close the interproximal contact? We keep our friends and get rid of our enemies.

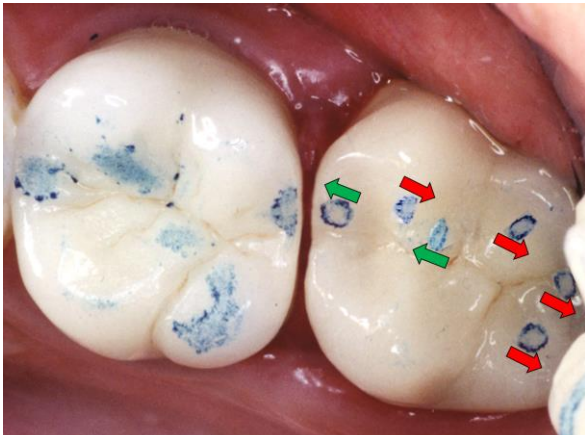
Walking the Tooth Mesially – the Rules

Marginal Ridges

- Keep any contact on the mesial marginal ridge (our very best friend)
 - This will help rotate the tooth mesially.
- Remove any contact on the distal marginal ridge
 - As the tooth rotates mesially, the distal half of the tooth (especially the distal marginal ridge) must “erupt” during rotation. You **MUST** relieve any contacts on the distal half of the tooth to allow the distal half to erupt. If the distal half of the tooth cannot erupt, the tooth cannot rotate mesially, and cannot close the open interproximal contact.

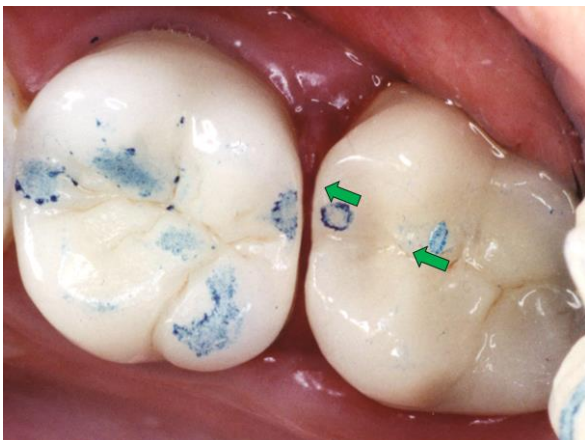
Cuspal Inclines

- Remove any contacts on mesial inclines found on the mesial half of the tooth. These contacts cause distalizing force and will prevent the tooth from migrating mesially.
- Keep any contacts on distal inclines found on the mesial half of the tooth. These will result in mesial vectors of force, moving the tooth mesially.
- Remove any contacts of any kind on the distal half of the tooth to allow the distal half of the tooth to erupt as the tooth tilts mesially.



On the left I show a photo of a tooth after it has distalized. I've placed green arrows (friends) showing the direction these forces want to move the tooth. These are the mesial marginal ridge and the distal incline on cusps on the mesial half of the tooth.

I show red arrows (enemies) showing the direction these forces want to move the tooth. These are the mesial inclines on the mesial half of the tooth, as well as ANY CONTACT OF ANY SORT on the distal half of the tooth.



Using your favorite burs for occlusal adjusting, remove any "enemy" articulating paper marks (achieved during centric occlusion and all possible excursions). Only remove enough tooth structure so that when you use articulating paper again, you do not see enemy contacts.

The result is what you see on the left, with only seeing "friendly" articulating marks.

Over the following 2-3 weeks, as the tooth moves (rotates) mesially, everything will change. Usually the distal half of the tooth will erupt and come into occlusion again. As soon as this happens, further mesial movement is halted.

Schedule the patient for visit #2 in 3 weeks. Follow the same process – keep your friends and get rid of your enemies. Then see the patient again in another 3 weeks.

You will find that it normally takes 2 occlusal adjustment visits, 3 weeks apart, to fully close the open space. Occasionally it will take only one adjustment visit. Occasionally it will take 3 or 4 adjustment visits.

As you can see, this is done in steps – thus why I term this technique "Walking Forward".

Are We Done?

No. We're not done yet. We need to STABILIZE IT.

When you see the patient and find a fully closed contact, you need to stabilize it to ensure the contact will stay closed.

You will simply follow the same occlusal adjustment technique of keeping your friends and eliminating your enemies. But this time, only adjust the occlusion until you see:

- Heavy friendly articulating paper marks.
- Very, very light, or no, enemy articulating paper marks.

Other Considerations

Mesial marginal ridges – The most effective occlusal contacts – by far – are the contacts on the mesial marginal ridges. But what if your lab didn't give you a good mesial marginal ridge? What if the marginal ridge is totally out of occlusion? Contacts on the distal cuspal inclines on the mesial half of the tooth will work, but much more slowly.

If this is the case, I would recommend creating a contact on the mesial marginal ridge in one of two ways:

- 1) Add a contact to the mesial marginal ridge with composite (even if you leave it there only temporarily until the tooth is back into proper position). Nowadays we have bonding options to bond to metal, porcelain and any material.
- 2) Add a contact to the opposing tooth where it would hit the mesial marginal ridge. Again, this may only be temporary, to be removed upon full closure of the open interproximal contact.

Mesial Marginal Ridge Bonding Options:

- **Bonding to composite resin restorations:**

- Treat existing composite resin you intend to bond to with Add & Bond by Parkell – this product is a MUST for every dental practice. It will allow you to add composite securely to temporaries (you can even add to the interproximal contact area), existing composite restorations that may be cracked and even dentures. Order at www.Parkell.com.

- **Bonding to porcelain**

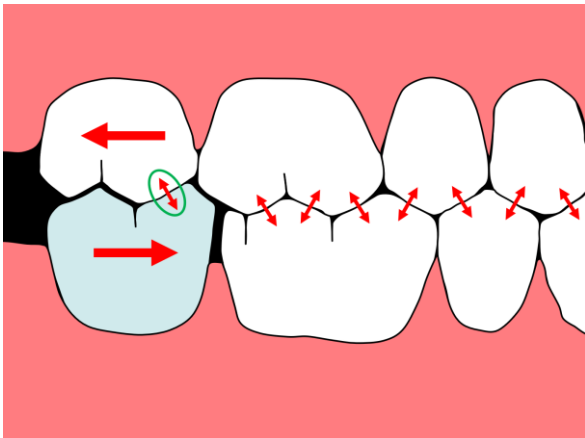
- Clearfill Repair by Kuraray (probably your best choice)
- Ultradent Porcelain Repair Kit
- Porcelain Etchant by Bisco
- PorceLock Porcelain Etchant by DenMat
- PorcelEtch Porcelain Etchant Kit by Cosmedent
- CEREC Ceramics Etch

- **Bonding to gold/metal**

- Alloy Primer by Kuraray (probably your best choice)
- Metalprimer II by GC
- Meta Fast Bonding Liner by Sun Medical Co.

For those physicists in the group – If you're a very scientific thinker, you may be saying, "But wait a minute Rod! What about Newton's Third Law of Physics!" This is the law that states, "For every action, there is an equal and opposite reaction."

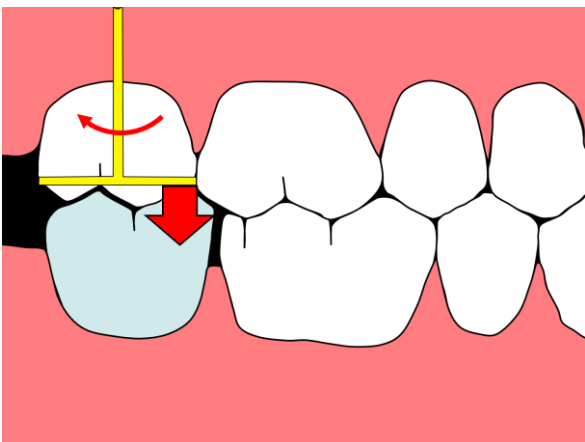
You may be wondering why the forces (applied by the opposing tooth) to distal cuspal inclines, moving the offending tooth mesially, do not also move the opposing tooth distally. If you're wondering this – good on you! It's a very rational concern. But it's not a problem – here's why:



To the left you see where the "enemy" occlusal contacts on the distalized crown have been removed. So, the only contact is on the distal incline of a mesial cusp. There may or may not be a mesial marginal ridge contact.

Notice the vectors of force shown as a double-ended red arrow with a green circle around it. You have force wanting to move the lower crown mesially – but you also have force wanting to move the upper 2nd molar distally. And there is no tooth distal to that upper 2nd molar – so WHY won't that upper 2nd molar move distally, opening up the interproximal contact on the upper?

I previously asked you to remember the concept that teeth move via rotation. Well, here ya go...



For that upper tooth to move DISTALLY, it would have to ROTATE DISTALLY, which means that the mesial half of the tooth would have to erupt. But the mesial half of the upper molar cannot erupt downward to allow distal rotation because of the contact you see (double-ended red arrow inside the green circle). This contact WILL push and rotate the lower crown mesially to close the unwanted open interproximal contact (because rotation will cause the mesial half of the lower crown to intrude just a little), but the same contact between upper and lower teeth will prevent the mesial half of the upper tooth from erupting, neutralizing the distalizing force on the upper molar.

This is why we virtually never see the opposing tooth distalize.

Other Benefits

Use this knowledge from now on during every crown insert – especially the terminal teeth in each quadrant. Make sure that you approach any new crown insert (especially the terminal posterior teeth in each quadrant) with the same goal you'd have when you "stabilize" the occlusion. Good, strong friendly marks, and very light, or no, enemy marks.

And don't let your lab get away with sending you crowns without good occlusion on the mesial marginal ridges!

Scroll down to see the step-by-step chairside summary